

## Examination report

0610202016603

(Formulated by the Netherlands Veterinary Association of the Royal Netherlands Veterinary Association.  
The pre-purchase examination was performed using the handbook "De veterinaire keuring van het paard" issue 2007 as a guidance).

Client: *Youngsters VOF*

Address: *Geerenweg 2*

Zip code / City: *3755 NM Eemnes*

Client is present at the exam : *yes*

Client is : *seller*

Level of training :

Proposed use : *sport*

Location where the exam takes place: *Waaij Stud*

## Signalment

Name: *Caffee Noir*

Breed or type: *Holsteiner*

Studbook no: *DE421000047214*

Microchip number: *276020000416603*

Pedigree: *Casalito x Cleanway*

Age: *6 years and 5 months* Sex: *gelding*

Coat color: Height at withers : *0.0*

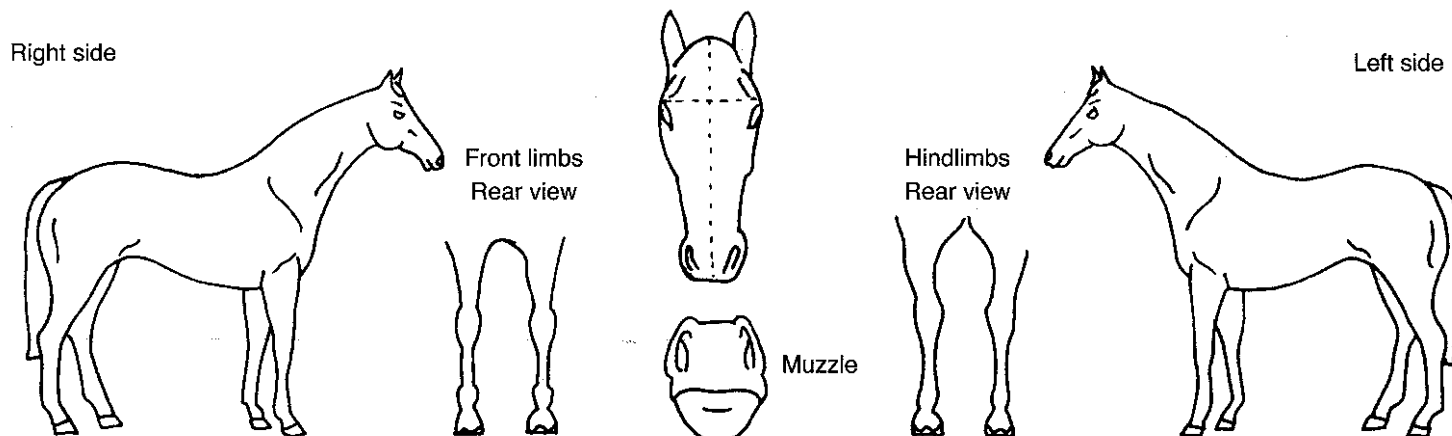
## Markings

Head: *See passport*

LF: LH:

RF: RH:

Other:



Evidence seen of possible behavioural vices?: *no*

Blood collected and put into custody by the examining veterinary surgeon?: *no*

Blood sample tested for prohibited substances at client's request?: *no*

Veterinary practice (stamp):

## CONCLUSION:

*The horse is sound and fit for proposed use.*

1. The examining veterinary surgeon and/or veterinary practice shall not be held liable for loss or damage caused as a result of the performance of the examination or as a result of inaccuracies or shortcomings in their preparation of this report, unless it has been established that this loss or damage is due to malice or negligence on the part of the examining veterinary surgeon.

2. The client shall have the sole right to invoke any action due to liability on the part of the examining veterinary surgeon and/or veterinary practice as described under 1 above. Parties other than the client shall not be entitled to derive any rights to compensation for damages arising from this examination/report.

3. Liability shall be limited at all times to that amount covered by the veterinary surgeon's professional indemnity insurance applicable at the time of the examination. Details of this coverage in the form of policy documents for this insurance may be inspected at the veterinary practice premises, and copies of these may be obtained at first request from the veterinary practice at no charge.

4. The provisions printed on this examination report shall also apply in the event the client fails to sign this form, or refuse to accept receipt of this examination report.

5. If the client upon whose instructions the examination was performed is not the owner of the horse, the client is wholly responsible for having obtained the owner's consent to all procedures performed during the examination, and the client shall fully indemnify the veterinary surgeon in respect of any claim by the owner arising from an allegation that such consent was not given.

6. In the event the client and/or third parties are of the opinion that the health of the horse at the time of the present examination does not correspond to that which is stated in the examination report, these parties must report this to the other party without delay and in writing (for example, together with the purchase contract), under penalty of the lapsing of every right of action against the examining veterinarian and/or the veterinarian practice, and to hold this party liable for compensation, while also simultaneously providing a copy of this report to the examination veterinarian and the veterinarian practice.

7. The laws of the Netherlands shall apply exclusively to any disputes arising from the performance of the examination and/or the completion of the examination report, and the Court of the Netherlands shall retain sole jurisdiction to hear these disputes.

8. In the event of differing interpretations between the Dutch and English text of these conditions, the content of the Dutch text shall be decisive.

Thus examined and reported by me:

*Drs. Willem van Kampen*

veterinary surgeon in:

*Stellingenweg 10*

*8474 EA Oldeholtpade*

This report can relate only to the appearance on the date of examination: *06-10-2020*

**General and clinical examination**

conformation and stance	normal
condition	normal
skin and coat	normal
mucous membranes	normal
lymph nodes	normal
eyes and eyelids	normal

**Respiratory system**

respiration at rest	normal
type of respiration	normal
spontaneous coughing	no
larynx sensitivity	normal
respiration after exercise	normal
abnormal sounds	no
laryngoscopy performed	no
laryngoscopy findings	no indication

**Circulatory system**

peripheral circulation	normal
heart at rest	normal
heart after exercise	normal

**Digestive system (ext. insp.)**

mouth, teeth, tongue	normal
----------------------	--------

**Urogen. system (ext. insp.)**

	normal
--	--------

**Nervous system**

tail tone	normal
correction reflexes	normal
coordination	normal

**Inspection, palpation and eventual percussion**

head	normal
neck	normal
withers	normal
back	normal
croup	normal
left frontlimb	normal
right frontlimb	normal
left hindlimb	normal
right hindlimb	normal

**Hooves**

horn quality	normal
horn percussion	normal
hoof shape	even .... higher than ....
shoeing	front and hind
type of shoeing	Normal

**Walk, trot and canter****Walking on hard surface**

straight line	normal
small circle on the left	normal
small circle on the right	normal

**Trotting on hard surface**

straight line	normal
small circle on the left	normal
small circle on the right	normal

**Trotting on soft surface**

small circle on the left	normal
small circle on the right	normal

**Cantering on soft surface**

small circle on the left	normal
small circle on the right	normal

**Flexion tests**

Forced flexion:	Trotting after 1 min. flexion:
LF not sensitive	LF -
RF not sensitive	RF -
LH not sensitive	LH -
RH not sensitive	RH -

**Radiological examination performed: yes**

Number of X rays:	26
-------------------	----

**Assessment of radiographs:**

	<b>Grading</b>
Navicular bone	LF 2 / RF 2
Fetlock joint	LF 2 / RF 2
Sesamoid bones	LF 2 / RF 2
Tarsal joint	LF 2 / RF 1

**Fragments**

Fetlock joint	LF -
Fetlock joint	RF -
Stifle joint	LH -
Stifle joint	RH -
Tarsal joint	LH -
Tarsal joint	RH -
Fetlock joint	LH -
Fetlock joint	RH -

**Radiological exam of other parts/extra findings:**

*Left hind proximal P1 shows a discrete vascular channel arising from the sagittal groove into the subchondral bone: acceptable finding*

*Left hind and right hind stifle small periarticular osteophyte of the medial tibial condyle: acceptable finding*

**Other remarks:**